

Anatomical Characteristics of the Conchal Cartilage With Suggested Clinical Applications in Rhinoplasty Surgery

Aesthetic Surgery Journal
30(4) 522–526
© 2010 The American Society for
Aesthetic Plastic Surgery, Inc.
Reprints and permission:
[http://www.sagepub.com/
journalsPermissions.nav](http://www.sagepub.com/journalsPermissions.nav)
DOI: 10.1177/1090820X10380862
www.aestheticsurgeryjournal.com


Arian Mowlavi, MD; Sylvia Pham; Bradon Wilhelmi, MD;
Shahryar Masouem, MD; and Bahman Guyuron, MD

Abstract

Background: Numerous cartilage grafts from a number of donor sites have been described, each with a different shape and size. These donor sites include the nasal septum, costal chondral cartilage, and the conchal bowl. Although harvests from the conchal bowl are commonly-employed, the techniques have been minimally-described in the literature, particularly as it applies to rhinoplasty.

Objectives: The authors identify differences in the conchal bowl cartilage parameters that could aid in the planning and harvesting of conchal grafts during augmentation rhinoplasty.

Methods: The authors dissected ears from fourteen cadavers (eight females and six males), ranging between 59 and 77 years of age. The conchal bowls were isolated, after which a reference point or was marked at the junction of the helical root and the conchal extension of the helical root. A cartilage grid was mapped out at 3-mm interval divisions with a horizontal limb axis parallel to the helical root extension and a vertical limb axis perpendicular to the latter. Conchal cartilage width, height, and thickness were then measured. Axial tissue slices were harvested and histologic preparations completed with hemotoxylin and eosin (H&E) staining to delineate microscopic characteristics of the cartilage.

Results: Maximum conchal bowl width ranged from 1.9 to 2.9 cm and was widest on average over the cymba (2.4 ± 0.3 cm). Maximum conchal bowl height ranged from 1.7 to 3.1 cm and was greatest on average over the region posterior to the junction of the helical root and conchal bowl (2.4 ± 0.5 cm). Conchal bowl thickness ranged from 1.9 to 4.4 mm and was observed thickest over both the conchal extension of the helical root (3.5 ± 0.4 mm) as well as over a distinct region in the inferior-anterior aspect of the cavum (3.7 ± 0.9 mm). No difference in thickness was observed between the conchal extension of the helical root (3.5 ± 0.4 mm) and the distinct region in the inferioranterior aspect of the cavum (3.7 ± 0.9 mm; $P > .05$). Naturally-occurring cartilaginous divisions were appreciated on histologic specimens located at the junction of the cavum and external auditory meatus and at the junction of the helical root and conchal extension of the helical root.

Conclusions: The results, examination, and outline of conchal bowl parameters from cadaver cartilage demonstrated in this article will aid the surgeon in effectively obtaining the appropriate cartilage grafts for placement during rhinoplasty.

Keywords

rhinoplasty, conchal cartilage, harvesting, grafting

Accepted for publication September 22, 2009.

Numerous cartilage grafts with varying shapes and sizes have been described for placement during rhinoplasty.¹⁻¹⁶ Donor sites include the nasal septum, the conchal bowl, and (less frequently) the costal chondral cartilage. Conchal cartilage is routinely harvested, especially during secondary rhinoplasty, when the nasal septum is not available.¹⁵ Despite wide utilization, the conchal bowl has been minimally described. The conchal bowl is composed of two components, the superior cymba and the inferior cavum, which are divided by the conchal extension of the helical root. The conchal bowl is bordered anteriorly by the helical root

Dr. Mowlavi is a Plastic Surgeon with Cosmetic Surgery Clinics, Laguna Beach, California. Ms. Pham is an undergraduate student at the University of California, Irvine, Irvine, California. Dr. Wilhelmi is the Chairman of Plastic Surgery at the University of Louisville, Louisville, Kentucky. Dr. Masouem is an Obstetrics & Gynecology Physician in Irvine, California. Dr. Guyuron is Professor and Chair, Department of Plastic Surgery, Case Western Reserve University, Cleveland, Ohio.

Corresponding Author:

Arian Mowlavi, MD, Cosmetic Surgery Clinics, Plastic Surgeon,
31542 Pacific Coast Highway, Laguna Beach, CA 92651, USA.
E-mail: amowlavi@gmail.com

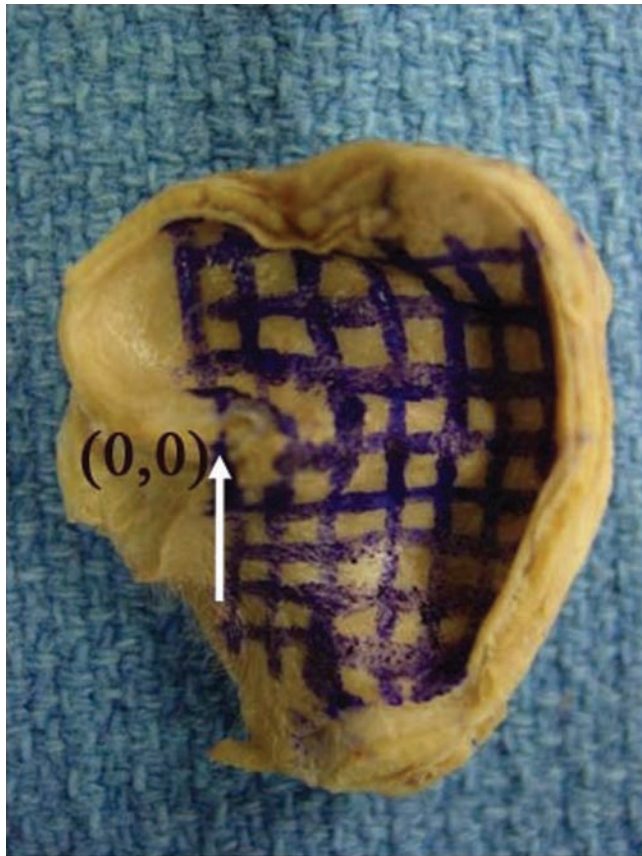


Figure 1. A left ear conchal bowl was characterized following the assignment of the reference point or origin (0, 0), at the junction of the helical root and the conchal extension of the helical root. A cartilage grid was then mapped out at 3-mm interval divisions with a horizontal limb axis parallel to the helical root extension and a vertical limb axis perpendicular to the latter.

and external auditory meatus. Posteriorly, the bowl is continuous, with side walls that are preserved during harvest to maintain structural stability of the ear. Except for the above anatomic descriptions, conchal bowl parameters have not been presented. In this report, we identify differences in the conchal bowl cartilage parameters that could aid in the planning and harvesting of conchal grafts during augmentation rhinoplasty.

METHODS

Fourteen cadaver ears (eight females and six males) ranging between 59 and 77 years of age were dissected and the conchal bowls were isolated. Subsequently, the lateral surface soft tissue was removed in order to expose a single cartilage surface in preparation for cartilage mapping. The reference point or origin (0, 0) was marked at the junction of the helical root and the conchal extension of the helical root (Figure 1). A cartilage grid was then mapped out at 3-mm interval divisions with a horizontal limb axis parallel to the helical root extension and a vertical limb axis

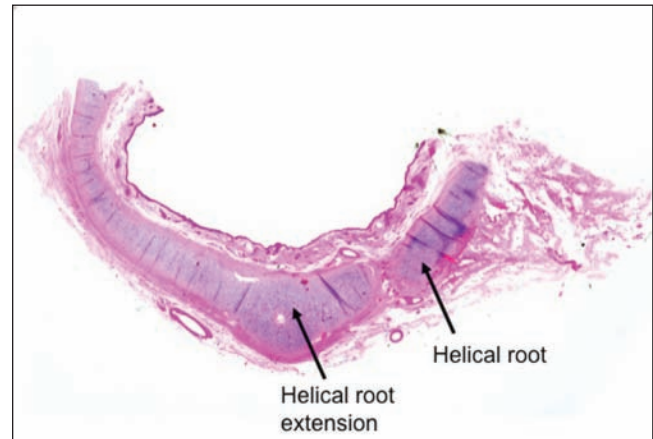


Figure 2. This cross-sectioned histologic specimen demonstrates the thickest region of the conchal bowl located over the conchal extension of the helical root. A natural division at the junction helical root to the helical root extension of the conchal bowl is appreciated.

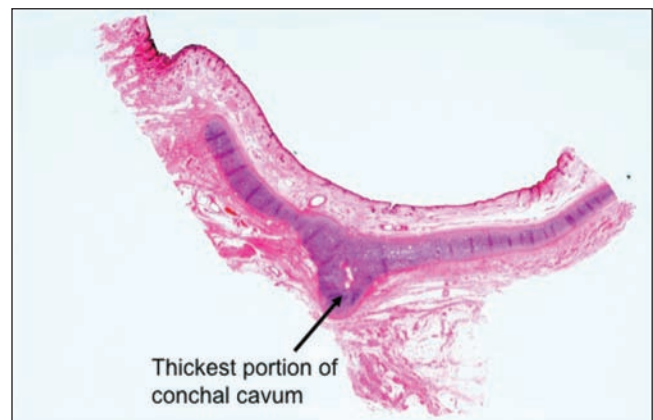


Figure 3. This cross-sectioned histologic specimen of the conchal cavum demonstrates the thickest region of the conchal bowl, located over a distinct thickening of the inferior-anterior aspect of the cavum.

perpendicular to the latter (Figure 1). Conchal cartilage width, height, and thickness were directly measured at the marked intervals using 40-times magnification microscopy. In addition, axial tissue slices were harvested and histologic preparations completed with hematoxylin and eosin (H&E) staining to delineate microscopic characteristics of the cartilage. All values were expressed as mean \pm standard deviation. Statistical analysis was performed with one-way analysis of variance (ANOVA) and post hoc Tukey tests, with statistical significance at $P < .05$ (Sigma Stat, San Rafael, California).

RESULTS

Maximum conchal bowl width ranged from 1.9 to 2.9 cm and was widest on average over the cymba (2.4 ± 0.3 cm) compared to the cavum (1.8 ± 0.2 cm, $P < .001$).

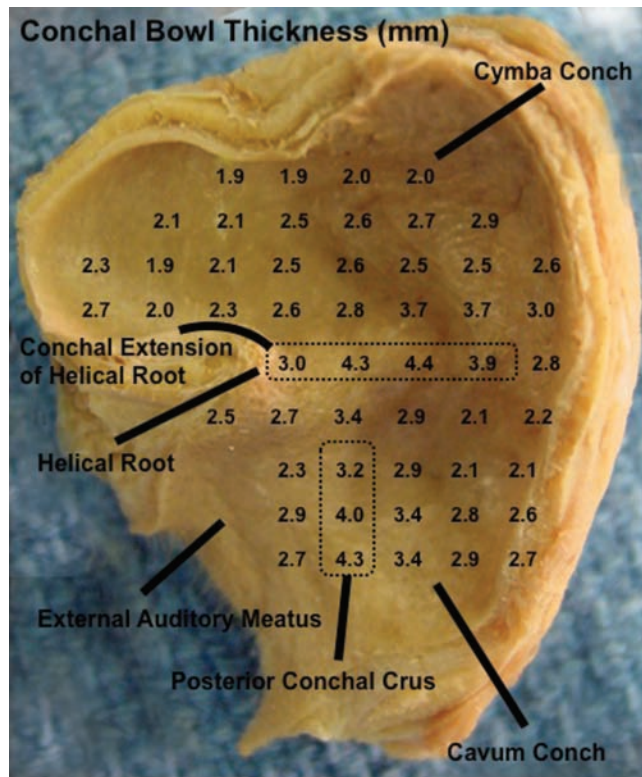


Figure 4. Conchal bowl thickness ranged from 1.9 to 4.4 mm and was observed at its thickest over both the conchal extension of the helical root (3.5 ± 0.4 mm; see Figure 2), as well as over a distinct region in the inferior-anterior aspect of the cavum (3.7 ± 0.9 mm), followed by moderate thickness over the conchal cavum (2.6 ± 0.5 mm) and minimal thickness over the conchal cymba (2.3 ± 0.4 mm; $P < .001$). No difference in thickness was observed between the conchal extension of the helical root (3.5 ± 0.4 mm) and the distinct region in the inferior-anterior aspect of the cavum (3.7 ± 0.9 mm; $P > .05$).

Maximum conchal bowl height ranged from 1.7 to 3.1 cm and was greatest on average over the region posterior to the junction of the helical root and conchal bowl (2.4 ± 0.5 cm) compared to the region anterior to the junction of the helical root and conchal bowl (1.7 ± 0.5 cm, $P < .001$). Conchal bowl thickness ranged from 1.9 to 4.4 mm and was observed thickest over both the conchal extension of the helical root (3.5 ± 0.4 mm; Figure 2) as well as over a distinct region in the inferior-anterior aspect of the cavum (3.7 ± 0.9 mm; Figure 3), followed by moderate thickness over the conchal cavum (2.6 ± 0.5 mm) and minimal thickness over the conchal cymba (2.3 ± 0.4 mm; $P < .001$; Figure 4). No difference in thickness was observed between the conchal extension of the helical root (3.5 ± 0.4 mm) and the distinct region in the inferior-anterior aspect of the cavum (3.7 ± 0.9 mm; $P > .05$). This distinct region over the inferior-anterior aspect of the cavum was noted to be protuberant over the medial conchal (ie, postauricular) surface, which was termed the

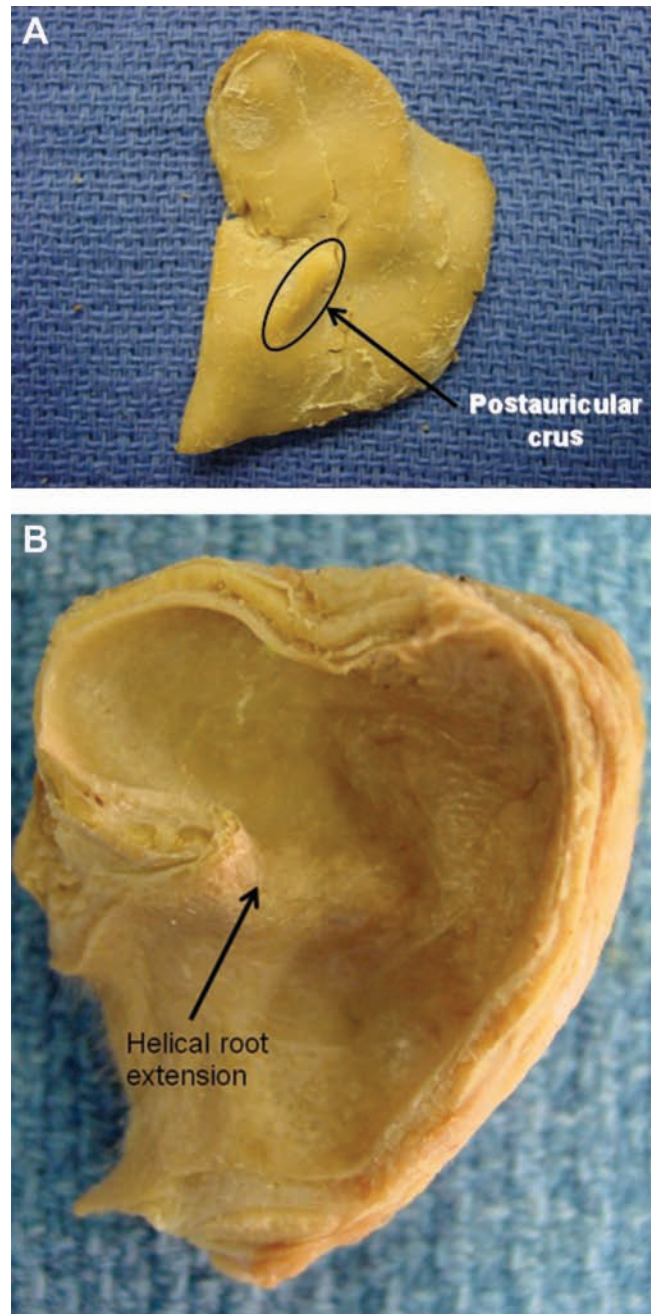


Figure 5. (A) Lateral and (B) medial (postauricular) conchal bowl surfaces. The two thickest areas in the conchal bowl can be appreciated and include the helical root extension of the concha prominent over the lateral surface and a distinct region in the inferior-anterior aspect of the cavum over the medial (postauricular) surface, termed the *postauricular crus*.

postauricular crus (Figure 5). Finally, naturally-occurring cartilaginous divisions were appreciated on histologic specimens located at the junction of the cavum and external auditory meatus (Figure 6) and at the junction of the helical root and conchal extension of the helical root (Figure 2).

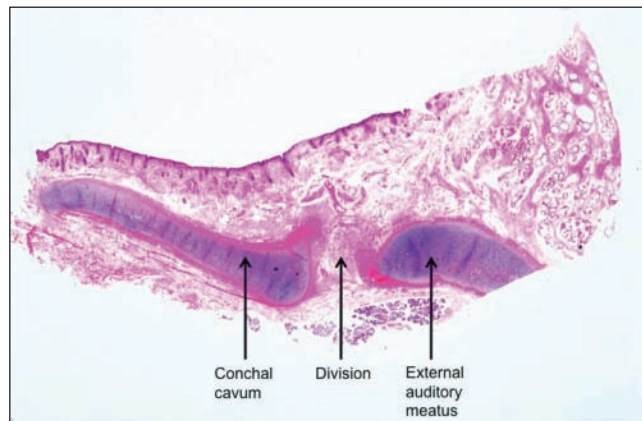


Figure 6. This cross-sectioned histologic specimen demonstrates a natural division between the conchal cavum and the external auditory meatus.

DISCUSSION

This study has defined conchal cartilage characteristics (width, height, and thickness) and identified differences in various bowl regions. With this knowledge, clinicians should be able to preoperatively select the suitable site for conchal graft harvesting. For example, it is noteworthy that the cymba is the widest yet thinnest cartilage region. This information may lead to the harvesting of a thin dorsal graft, which can be more readily camouflaged and will span both the upper and middle vaults if so desired. In addition, this area would offer an excellent choice for a tip graft or alar rim graft since these grafts often need to be supple in order to avoid unnatural prominences.⁷ It is notable that the cymba is routinely split from the cavum to be worked with individually. Some surgeons further split the cymba down the middle and apply a horizontal mattress suture at each end of the two halves, in order to create more manageable units of cartilage graft that are stronger and straighter.¹⁷

In contrast to the cymba, the extension of the helical root may be utilized to harvest a thicker graft such as a spreader,³ subdomal,⁶ or columellar strut graft.⁸ Finally, there may be occasion to choose a graft that requires variable surface thickness over its span. For example, it might be desirable to have a shield graft that is thinner over the infratip lobule yet more prominent underlying the tip defining points in patients with thick nasal tip skin. In the latter patient, a graft from the cavum that includes the firmer and thicker inferior-anterior region of the cavum would be an ideal choice.

Knowledge of conchal bowl span and natural divisions should be especially helpful during secondary rhinoplasty, where the suitable portion of the cartilaginous septum has been removed. In this situation, it is imperative to maximize harvested graft yield, which may be shortchanged if one does not harvest the entire conchal bowl. Limiting harvest material will only decrease graft resources and result in palpable ear irregularities.¹⁸ Finally, anterior dissection may be performed without injury to the external auditory meatus or helical

root if one utilizes knowledge of naturally occurring divisions found in these regions.

We prefer a postauricular approach to cartilage harvest following marking of the conchal bowl perimeter from a more direct lateral approach.¹⁸ The conchal bowl perimeter is marked following the junction of the bowl and the posterior side wall, as well as the helical root and external auditory meatus anteriorly, by through-and-through penetration of the concha with a methylene blue-stained 25-gauge needle. This aids in removal of sufficient graft material, while an adequate frame is maintained for the support of the ear. The conchal fossa is injected with xylocaine containing 1:100,000 epinephrine, in an attempt to hydrodissect the perichondrium. A postauricular incision is then designed on the postauricular skin and centered within the perimeter markings. After elevation of skin flaps and identification of the conchal bowl, the conchal bowl may be harvested again through the perimeter markings. Dissection should begin posteriorly through the side wall and bowl junction and then proceed anteriorly where there is less favorable visibility. The anterior dissection should require minimal effort since there are naturally occurring division lines at the helical root junction as well as the external auditory meatus junction. The posterior perichondrium may be preserved on the cartilage if one wishes to utilize this material for camouflaging of grafts during rhinoplasty. Great care must be taken to avoid injury to the anterior skin. Following harvest, the graft should be maintained in a moist environment. Meticulous hemostasis is achieved to prevent postoperative hematoma formation, the wound is irrigated with antibiotic solution, and the skin incision is repaired. We recommend a through-and-through stitch prior to closure of the postauricular skin through the anterior skin, the mastoid fascia, and then back through the anterior skin, in order to provide for a secure bolster dressing. This suture is tied over a moistened dental roll compressed into the conchal bowl void. Postoperatively, ointment is maintained on the incision line until postoperative day seven, when the bolster dressing is removed and ointment application discontinued.

CONCLUSIONS

Knowledge of facial anatomy is critical to a successful surgical outcome, especially during rhinoplasty. Our results, examination, and outline of conchal bowl parameters from cadaver cartilage will aid the surgeon in effectively obtaining cartilage grafts during rhinoplasty.

Disclosures

The authors declared no conflicts of interests with respect to the authorship and/or publication of this article.

Funding

The authors received no financial support for the research and/or authorship of this article.

REFERENCES

1. Guyuron B, Michelow BJ, Englebaldt C. Upper lateral splay graft. *Plast Reconstr Surg* 1998;102:2169-2177.
2. Toriumi DM, Josen J, Weinberger M, Tardy E. Use of alar batten grafts for correction of nasal valve collapse. *Arch Otol Surg* 1997;123:802-808.
3. Guyuron B, Poggi JT, Michelow BJ. The subdomal graft. *Plast Reconstr Surg* 2004;113:1037-1040.
4. Rohrich RJ, Hollier LH. Use of spreader grafts in the external approach to rhinoplasty. *Clin Plast Surg* 1996;23:255-262.
5. Constantian MB. The septal angle: a cardinal point in rhinoplasty. *Plast Reconstr Surg* 1990;85:187-195.
6. Sheen JH. Tip graft: a 20 year retrospective. *Plast Reconstr Surg* 1993;91:48-63.
7. Peck GC, Michelson L, Segal J, Peck GC. An 18-year experience with umbrella graft in rhinoplasty. *Plast Reconstr Surg* 1998;102:2158-2165.
8. Sheen JH. Spreader graft: a method of reconstructing the roof of the middle nasal vault following rhinoplasty. *Plast Reconstr Surg* 1984;73:230-239.
9. Gunter JP, Rohrich RJ. Correction of the pinched nasal tip with alar spreader grafts. *Plast Reconstr Surg* 1992;90:821-829.
10. Carolis VD. The infradome graft: a new technique to improve dome reshaping in rhinoplasty. *Plast Reconstr Surg* 1998;102:864-871.
11. Ortiz-Monasterio F, Olmedo A, Osoy LO. The use of cartilage grafts in primary aesthetic rhinoplasty. *Plast Reconstr Surg* 1981;67:597-605.
12. Hamra ST. Crushed cartilage grafts over alar dome reduction in open rhinoplasty. *Plast Reconstr Surg* 2000;105:792-795.
13. Gunter JP, Rohrich RJ. Lengthening the aesthetically short nose. *Plast Reconstr Surg* 1989;83:793-800.
14. Gruber RP. Lengthening the short nose. *Plast Reconstr Surg* 1993;91:1252-1258.
15. Daniel RK. Secondary rhinoplasty following open rhinoplasty. *Plast Reconstr Surg* 1995;96:1539-1546.
16. Endo T, Nakayama Y, Ito Y. Augmentation rhinoplasty: observations on 1200 cases. *Plast Reconstr Surg* 1991;87:54-59.
17. Gruber RP, Kryger G, Chang D. The intercartilaginous graft for actual and potential alar retraction. *Plast Reconstr Surg* 2008;121:288e-296e.
18. Guyuron B. Simplified harvesting of the ear cartilage graft. *Aesthetic Plast Surg* 1986;10:37-39.