

Implications for Nasal Recontouring: Nasion Position Preferences as Determined by a Survey of White North Americans

Arian Mowlavi, M.D., D. Garth Meldrum, M.D., and Bradon J. Wilhelmi, M.D.

Springfield, USA

Abstract. White North American men ($n = 75$) and women ($n = 75$) were surveyed to investigate gender specific preferences of nasion position, which may aid plastic surgeons in nasal shaping during rhinoplasty. The subjects were asked to rank preferences of various nasion positions from life-size, scaled, sketched male and female profiles. Nasion positions with regard to height (anterior projection) and level (vertical position) were altered, whereas all other facial and nasal anthropometric measurements were held constant. The nasion heights were drawn at 7, 10, and 13 mm anteriorly to the corneal plane, and the nasion levels were drawn at the supratarsal fold (ST), upper lid ciliary margin (CM), midpupil (MP), and lower limbus (LL). The rank selections made by the female and male subjects of both gender profiles demonstrated statistical significance, as demonstrated by one-way analysis of variance (ANOVA) of ranks ($p < 0.001$). Further analysis using a post-Dunn test was completed to delineate significant gender specific preferences for the aesthetic nasion level and height. Female nasion levels were preferred at CM or MP over LL or ST on the basis of female ranks, and at ST, CM, or MP over LL on the basis of male ranks ($p < 0.05$ for all comparisons). Additionally, female nasion heights were preferred at 10 mm > 13 mm > 7 mm anterior to the corneal plane on the basis of both female and male ranks ($p < 0.05$ for all comparisons). Male nasion levels were preferred at ST, CM, or MP over LL on the basis of both male and female ranks ($p < 0.05$ for all comparisons). Male nasion heights were preferred at 10 mm > 13 mm > 7 mm anterior to the corneal plane by both male and female ranks ($p < 0.05$ for all comparisons). In summary, both the male and female

subjects strongly disliked a low nasion height of 7 mm and a low nasion level placed at LL for both gender profiles. Both the male and female subjects were most particular concerning nasion height, preferring a 10-mm projection and strongly disliking a deeper 7-mm height for both male and female profiles. Both the male and female subjects were more tolerant of nasion level alterations. Whereas the male subjects tolerated nasion levels at ST, CM, or MP for either gender profile, the female subjects preferred only nasion levels at CM and MP for the female gender. Overall, these findings may lend support to recent trends in radix augmentation during rhinoplasty, especially among male patients.

Key words: Rhinoplasty—Nasal contouring—Radix

Deficiency in the radix is a commonly overlooked abnormality that may result in overzealous hump reduction. This is most evident in male patients, in whom inadvertent hump resection instead of radix augmentation may result in an undesired feminine look. This phenomenon has promoted a trend toward conservative hump reduction with maintenance of a “stronger nasal dorsum” profile [1]. Several clinicians have defined various guidelines for the purpose of aiding radix assessment preoperatively. Unfortunately, these guidelines often are subjective interpretations, and more importantly, nonspecific to the gender of the patient.

The radix may be judged by evaluating not only the position of the nasion, but also the nasal root contour. Prior reports have variably referred to the nasal root as the radix [3,21], the sellion [8,11,12], the soft tissue nasion [19], or the nasion [16,17]. Daniel [7] more accurately defined the nasion as the deepest point of the nasofrontal angle and the radix as an area centered around this point extending from

Accepted to the ASPS-PSEF-ASMS 2002 Annual Meeting

Correspondence to Arian Mowlavi, M.D., Plastic Surgery Resident, PGY5, The Plastic Surgery Institute, Southern Illinois University, School of Medicine, 747 N. Rutledge, P.O. Box 19653, Springfield, IL. 62794-9653, USA; *email:* amowlavi@hotmail.com

approximately the level of the eyebrow down to the intercanthal line. Moreover, the nasion is located at the midline and slightly inferior to the nasofrontal suture line [8]. Centered along the nasofrontal groove, the nasion has been localized to 5.8 mm above the intercanthal line. Thus, the nasion lies inferior to the nasofrontal suture notch, which lies 10.7 mm above the intercanthal line according to observations made in 60 cadavers [18]. Consequently, the nasion actually is an indentation of the nasal bones and not created by the intersection of two bony plates. When judging the radix lie, one may assess the level (vertical position) and height (the horizontal position or anterior projection) of the nasion as well as the nasal root groove angle, defined as the nasofrontal angle.

This nasofrontal angle is defined by the apex of the nasion and its two limbs: the glabellar limb extending cephalad from the nasion to the glabella and the nasal dorsum limb extending caudally from the nasion to the dorsal nasal hump. To normalize measurements, Daniel [10] prefers the lower limb to be drawn through the nasal tip to avoid distortion of the nasofrontal angle in patients with a prominent dorsal hump. This angle has been reported to vary from 128° to 140°, with the ideal angle defined as 134° in women and 130° degrees in men [12]. These parameters have been based on subjective anthropometric measurements of patients with attractive profiles, as determined by Farkas et al. [11].

Predominantly, the quality of the nasal profile is determined by the nasofrontal angle, a straight nasal dorsum, and the nasolabial angle. Whereas the nasolabial angle has been clearly defined and accepted as 105° to 108° in women and 100° to 103° in men [16], the nasofrontal angle has not been as thoroughly examined. As previously mentioned, this angle is influenced not only by its two limbs, but also by the position of the nasion, defining the angle apex. In fact, Daniel [7] emphasized the significance of considering the nasal root area during rhinoplasty by advocating nasion positioning before modification of either the nasal dorsum or tip projection.

The nasofrontal angle is influenced by the slope of the forehead, which affects the glabellar point and thus its cephalic glabellar limb [6]. The glabella can be defined as the most prominent midline point between the eyebrows in the anterior view and as the most protruding anterior point on the forehead at or just inferior to the level of the eyebrows in profile view [7]. The glabellar contour can influence the nasofrontal angle, ranging from a sharper notch to a gentle concave curve. The sharper or more deeply recessed angle can create a shadowing that results in an unattractive “beetling” look [24]. Webster et al. [24] have commented that a prominent radix with a shallow nasofrontal angle may have been desired by the Romans and Greeks, but would be considered too masculine and unattractive for a female. Conversely, a soft nasal dorsum with a deeper nasofrontal angle

may result in a feminine look that would not be desired for a male patient. Ideally, an aesthetically positioned nasofrontal angle that takes into account the gender of the patient would provide a smooth and desired junctional end of the forehead and beginning of the nose. Because most patients are not willing to alter the bony forehead area, the nasofrontal angle can be altered only by revising its caudal limb, as influenced by the nasal dorsum plane, or by altering its apex, as defined by the nasion.

To date, the desired level and height of the nasion have been variably described and not delineated with respect to the patient’s gender. The nasion level has been reported to span between the supratarsal fold and eyelashes of the upper eyelid [8]. Guyuron [16] prefers placement of the nasion level at the lower border of the upper lid margin on a straightforward gaze. Yet, this specification allows the nasion level to vary over a 12-mm range [7]. Furthermore, Sheen [20] noted that a lower level of the nasion, (e.g., at the pupil) may provide softening of the profile, which may be desired in certain cases.

Similarly, the height of the nasion has been non-uniformly described using various anatomic landmarks. One investigator advocated that the nasion should be positioned no less than 15 mm and no more than 20 mm from the medial canthus on the basis of his observations [14].

Another landmark involves the corneal plane defined by the vertical tangent to the corneal surface. Using this landmark, the height has been noted to fall an average of 11 mm (range, 9–14 mm) from the corneal plane, as measured directly from patient profiles [3]. Specifically, this radix projection has been delineated as equal to one-third of the nasal length ($0.28 \times$ the nasal length) on the basis of measurements taken on 87 models determined by authors as having superior aesthetic facial features [3]. Finally, Guyuron [16] prefers the nasion height set 4 to 6 mm behind the glabellar line on the basis of his personal observations using 1,619 life-size, scaled profile photographs [16].

We attempted a more accurate identification of the aesthetically pleasing radix lie, paying special attention to any gender differences of the nasion height and level by surveying white North American women and men. Each subject was asked to choose among life-size, scaled, sketched male and female profiles while varying the nasion level (vertical position) as well as the nasion height (horizontal position).

Methods

White North American women ($n = 75$) and men ($n = 75$) were surveyed to determine their preferred ideal radix lie by varying the nasion position. The subjects were white adult men or women ages 18 to 65 years at varied education levels. They were asked

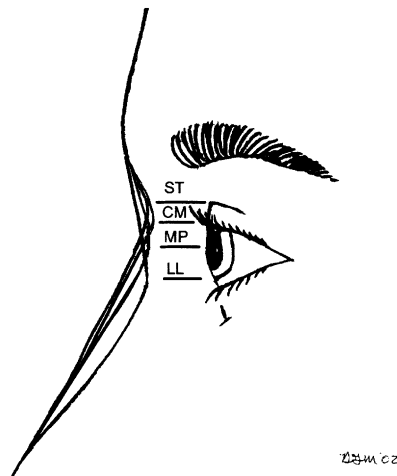


Fig. 1. Nasion level (vertical position) at four separate positions: supratarsal fold (ST), ciliary margin of the upper lid (CM), midpupil (MP), and lower limbus (LL).

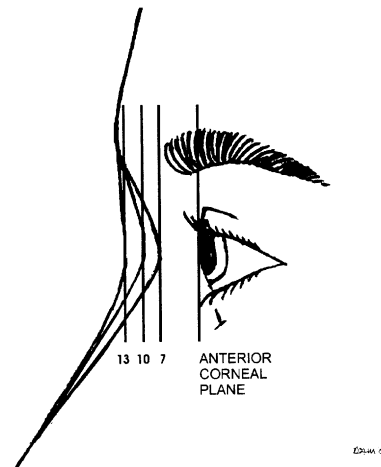


Fig. 2. Nasion height, as defined by the projection of the nasion beyond the anterior corneal plane, at distances of 7, 10, and 13 mm anterior to the corneal plane.

to choose from among 25 life-size, scaled sketches of white North American female and male faces drawn using facial and nasal anthropometric measurements. To avoid any confounding effects of intersubject profile preferences, all facial features except the altered radix area were held constant on the basis of facial and nasal anthropometric measurements. Black and white profile sketches were used to avoid any confounding effects from variability in skin contour, eye color, and hair style that would be apparent in the evaluation of life-size photographs or models. The nasion level (vertical position) was presented in four separate positions: supratarsal fold (ST), ciliary margin of upper lid (CM), midpupil (MP), and lower limbus (LL) (Fig. 1). Furthermore, each of these nasion levels was presented at nasion heights of 7, 10, and 13 mm anterior to the corneal plane (Fig. 2).

Life-size profile views were designed with the head in the Frankfort horizontal plane (FHP), as defined by the horizontal plane passing through the most cephalad aspect of the external auditory meatus and the inferior orbital rim. Thereafter, appropriate orientation of this plane was verified by drawing a line from the radix area to the most prominent tragal point, which formed 69° with the vertical facial plane, defined by a vertical line passing through the nasion [16]. Because the infraorbital rim in profile images or photography cannot be accurately assessed, Guyuron [16] defined this nasotragion plane to vertical facial plane as an angle of 67° to 73° (average, 69°) to confirm appropriate FHP positioning on two-dimensional images.

The sketch profile approximated a previously accepted aesthetic facial profile model showing a forehead and chin that were minimally retrodisplaced with respect to the midface [2]. Moreover, standard aesthetic planes were used such that the glabella and upper lip lay in a single line perpendicular to the FHP. Moreover, vertical inclinations were normal-

ized on the basis of measurement averages from 51 white men and 50 white women ages 18 to 30 years of age previously published by Farkas et al. [13]. Standard vertical heights were used for the glabella to pogonion (-4.7 for men; -4.9 for women), glabella to subnasalis ($+1.3$ for men; -0.1 for women), and subnasalis to pogonion (-16.2 for men; -14.1 for women) distances. Additionally, the facial vertical height parameters were cross-referenced to previously described measurements taken from 103 white North American individuals [10]. The vertical heights of trignon to nasion, nasion to subnasale, and subnasale to gonion demonstrated a gradual increase in length from cephalad to caudal positions, as compared with the previously established cannon of equal one-third distances [10].

To normalize the effect of the glabellar limb on the aesthetic profile and corneal plane measurements, the orbitoglabellar distance, as defined by Farkas [9], and a corneal to glabellar vertical plane distance were measured and equalized for both the female and male profiles. The orbitoglabellar distance was defined as the oblique distance from the lateral canthus to the glabella [9]. The corneal plane was defined as the vertical line passing through the cornea, and the glabellar vertical plane similarly as that passing through the glabella. The glabella was defined by the most prominent surface point overlying the frontal bone between the eyebrows [11].

The forehead was designed in a aesthetically pleasing convex contour, with the apex set at the glabella, as depicted by Daniel [6], and with a forehead inclination of -10.5 for men and -5.5 for women [13]. The nasal length was designed to be generally shorter (47 to 53 mm) than the ear (60.4 mm) and the inclination greater, more horizontal, than the ear [10].

Finally, the nasal profile was standardized with respect to the nasal tip, nasolabial angle, and nasal

dorsum. The nasal tip projection was approximated by the distance from the stomion to the menton [3]. This length was cross-referenced by its equality to 0.44 times the midfacial height (MFH), defined as the length from the glabella to the alar base planes [3]. Next, the nasolabial angle was determined by drawing limbs from the subnasalis to the infratip break as well as a vertical line perpendicular to the FHP and passing through a point 1 to 2 mm posterior to the most projected portion of the upper lip (labrale superius). The subnasalis was designated as the intersection of a horizontal line drawn parallel to the FHP and passing through a point 2 to 3 mm above the junction of the lower one-third and upper two-thirds divisions, respectively, for the stomion to radix vertical height and the vertical facial plane line [16]. The nasolabial angles subsequently were verified to fall between 90 and 95 for the male and 95 to 100 for the female. Finally, the nasal dorsum in the female sketch was placed approximately 2 mm behind and parallel to the line from a point just above the nasofrontal angle to the nasal tip. Conversely, in the male profile, the dorsum was drawn slightly higher. The nasal dorsum was drawn to correlate with Guryon's [16] work demonstrating that the nasal bridge is not a straight line and maintaining a 0.75 to 1-mm-deep curve for men and a 1.5 to 2.0-mm-deep curve for women. The nasal dorsum was created to provide a nearly linear lie as described earlier, and was oriented at approximately 30° to the vertical [14]. This nasal inclination was based on previous reports demonstrating an average of 29.5 for men and 29.6 for women [13].

After all the completed surveys had been collected, rank orders were calculated and statistical analysis was completed using SigmaStat (version 2.3, San Rafael, CA, USA). One-way analysis of variance (ANOVA) of ranks was completed for each of the rank orders. Additionally, a post-Dunn test was used to delineate significant gender-specific preferences for the aesthetic nasion level and height.

Results

The rank selections made by the female and male subjects for both gender profiles demonstrated statistical significance, as demonstrated by one-way ANOVA of ranks ($p < 0.001$ for each of the rank orders) (Figs. 3 and 4). Further analysis using a post-Dunn test demonstrated that female nasion levels were preferred at CM or MP over LL or ST on the basis of female ranks, and at ST, CM, or MP over LL on the basis of male ranks ($p < 0.05$ for all comparisons) (Fig. 3). Additionally, female nasion heights were preferred at 10 mm > 13 mm > 7 mm anterior to the corneal plane on the basis of both female and male ranks ($p < 0.05$ for all comparisons) (Fig. 3). Male nasion levels were preferred at ST, CM, or MP over LL on the basis of both male

and female ranks ($p < 0.05$ for all comparisons) (Fig. 4). Male nasion heights were preferred at 10 mm > 13 mm > 7 mm anterior to the corneal plane by both male and female ranks ($p < 0.05$ for all comparisons) (Fig. 4).

Discussion

Various guidelines have been presented using various anatomic landmarks to guide radix lie positioning preoperatively. In general, Daniel [7] advocated that placement at a higher supratarsal fold provides a stronger nasal profile, whereas placement at the pupil provides a softer profile. Similarly, Gunter [15] advised that there are no strict parameters for determining the depth and angle of the nasofrontal angle, and that aesthetic judgment must be used to determine whether it is too shallow or deep. Indeed, such variable guidelines may prove difficult to use, especially considering potential gender differences. A retrospective study of 150 consecutive secondary rhinoplasties determined that a low radix and low dorsum was the most common deficiency detected in 93% of patients [5]. Although Sheen and Sheen [22] along with others have identified the low radix/low dorsum as a primary cause of nasal imbalance, there still remains a lack of gender-specific guidelines [4]. This imbalance has been characterized by an overly prominent depression or notch in the radix area [22] or a relatively linear dorsum that is too shallow in relation to the nasal base [4].

Using sketched profile images, the level and height of the nasion were varied while other facial parameters were held constant to determine the preferred radix lie, as assessed by 75 female and 75 male white subjects. Both male and female subjects strongly disliked placement of a low nasion height of 7 mm and a low nasion level at LL for both gender profiles. Both the male and female subjects were most particular concerning nasion height, preferring a 10-mm projection and strongly disliking a deeper 7-mm height for both male and female profiles. All the subjects were more tolerant to nasion level alterations. Whereas the male subjects tolerated nasion levels at ST, CM, or MP for either gender profile, the female subjects preferred nasion levels only at CM and MP for the female gender. Overall, these findings emphasized a unanimous preference for nasion height and slight gender-specific differences with regard to the nasion level.

The radix spans a region from the cephalic thick skin of the infraglabellar area (measuring up to 9.5 mm) to the thin skin of the nasal dorsum (measuring as thin as 3.5 mm) [6]. Adipose tissue is found underneath, spanning from the underlying muscles to the dermis. The underlying muscle includes the procerus, which is divided into a horizontal bundle that fuses in the midline with its contralateral counterpart, as well as an oblique bundle that passes from the upper lateral cartilage to the glabella [6].




Fig. 3. Illustrations and rank orders of the female and male preferences for the female nasion position. The selection made by the female and male evaluators demonstrated statistical significance within each of the rank orders as demonstrated by one-way analysis of variance ($p < 0.001$). Further analysis using a post-Dunn test demonstrated that female nasion levels were preferred at the ciliary margin of the upper lid (CM) or the midpupil (MP) over the lower limbus (LL) or the supra tarsal fold (ST) on the basis of female ranks, and at ST, CM, or MP over LL on the basis of male ranks ($p < 0.05$ for all comparisons). Additionally, female nasion heights were preferred at 10 mm > 13 mm > 7 mm anterior to the corneal plane on the basis of both female and male ranks ($p < 0.05$ for all comparisons).

Additionally, the corrugator originates from the frontal bone and inserts into the skin beneath the eyebrow, determining the curve of the dorsal lines into the supraorbital ridges. Despite the amount of

soft tissue, the nasofrontal angle is defined ultimately by the underlying bony structures. Whereas the nasofrontal suture is located 10.9 mm above the intercanthal line, the nasofrontal angle apex is found

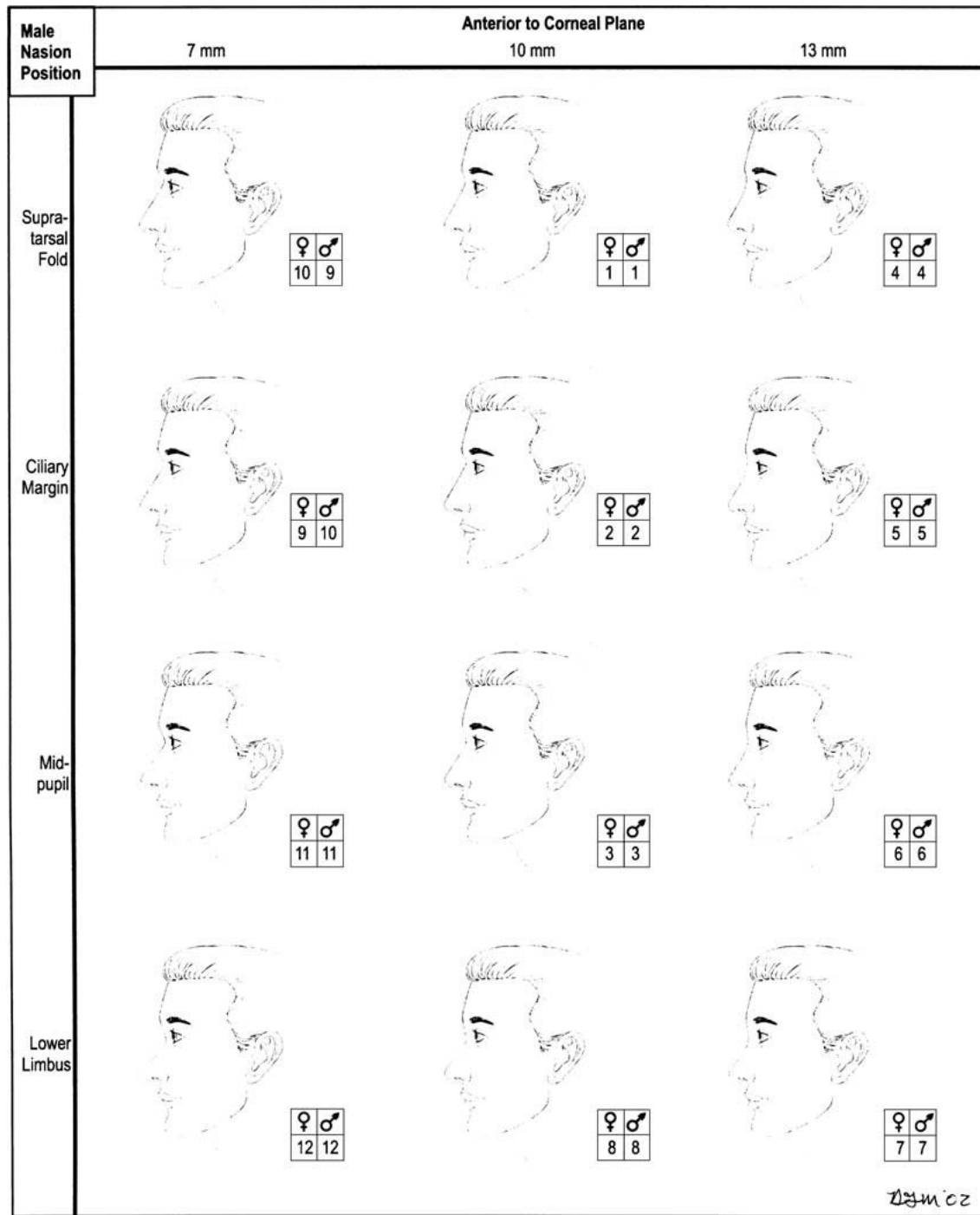


Fig. 4. Illustrations and rank orders of the female and male preferences for the male nasion position. The selection made by the female and male evaluators demonstrated statistical significance within each of the rank orders, as demonstrated by one-way analysis of variance ($p < 0.001$). Further analysis using a post-Dunn test demonstrated that male nasion levels were preferred at the supratarsal fold (ST), the ciliary margin of the upper lid (CM), or the midpupil (MP) over the lower limbus (LL) on the basis of both male and female ranks ($p < 0.05$ for all comparisons). Male nasion heights were preferred at 10 mm > 13 mm > 7 mm anterior to the corneal plane by both the male and female ranks ($p < 0.05$ for all comparisons).

inferior to this point at 4.9 mm above the intercanthal line [6], defined solely by the groove in the nasal bone. If augmentation is chosen, the graft must extend down to the caudal radix border (i.e., nasal

dorsum junction), which can be approximated by drawing a line through the lateral canthus [6].

Although this study evaluated the profile characteristics of the radix, the horizontal component of this

area also should be considered. Horizontal to vertical parameters are interlinked by the alar base width, which should be equal to the intercanthal distance, one eyes width, and the nasal tip projection. The nasal tip projection subsequently defines the nasal length, the distance from the nasal tip to the nasal root. The ideal tip projection, defined by the distance from the anterior nasal spine to the nasal tip, should be equal to 0.66 times the ideal nasal length [15]. Moreover, the nasal length can be approximated as two-thirds of the midfacial height [3]. Additionally, the radix width has been defined as equal to 50% of the interpupillary width according to a study of 34 attractive young North American women and the subjective determination of the study authors [11]. This measurement is obviously an approximation that may be altered in patients with hypertelorism or those with variant lateral wall angles [7].

The nasion height (anterior projection) and the nasion level (vertical position) defined the nasofrontal apex, which influences the nasofrontal angle and the nasofacial angle. The nasofrontal angle is an important parameter of nasal profile evaluation in that it determines the visual projection of the nose from the face independently of the tip position [22]. The angle is defined by vectors starting at the nasion and directed cephalad toward the infrabrow glabellar area and the vectors directed caudally toward the nasal dorsum. Furthermore, the nasion height and level affect the visual projection of the nose on an anteroposterior facial analysis. This visual projection of the nose from the face is most influenced by the nasofacial angle, which is set at 34° in women and 36° in men as determined by Farkas and Munro [12]. The nasofacial angle is formed by the intersection of the facial plane and the dorsal plane [21]. If the radix is placed too inferiorly, then the nose appears foreshortened and the nasal tip and base disproportionately large, as typified by larger nasofacial angles (~55°). If the radix is moved cephalad, then the nose appears longer and the nasofacial angle more acute (~25°). Our study reiterates these points by demonstrating the dislike of both genders for placement of the nasion level at the LL, which would theoretically create a foreshortened nasal appearance.

To date, the deepest aspect of the nasofrontal angle (i.e. the nasion apex) has most commonly been portrayed at the ST fold with the eyes in forward gaze [16]. Interestingly, the nasion position can vary, with commonly observed combinations of level and height including a cephalad level combined with increased height, and a caudal level combined with low height [6]. As such, if a low radix disproportion is not recognized and hump reduction performed, overreduction of the nasal dorsum is created. With the increasing recognition of the benefits associated with a more conservative, preservationist approach to rhinoplasty, emphasis has been placed on maintaining a high, strong profile [25]. Radix augmentation may be increasingly indicated, especially for male

patients because men were preferred at the ST, CM, or MP nasion level as opposed to the LL. Further evidence for radix augmentation in shallow nasion heights was evident by the significant dislike of both the men and women for the low 7-mm anterior projection in this survey. Whereas, a nasal dorsum with a straight profile or a slight concavity at the rhinion currently is generally considered the aesthetic ideal for the white female nose, a high dorsum that is straight or with a slight hump may be considered the ideal for the white male nose [23]. Overall, these findings may lend further support to recent trends in radix augmentation during rhinoplasty, especially for the male patient.

References

1. Becker DG, Pastorek NJ: The radix graft in cosmetic surgery. *Arch Facial Plast Surg* **3**:115–119, 2001
2. Borman H, Ozgur F, Gursu G: Evaluation of soft tissue morphology of the face in 1,050 young adults. *Ann Plast Surg* **42**:280–288, 1999
3. Byrd S, Hobar PC: Rhinoplasty: a practical guide for surgical planning. *Plast Reconstr Surg* **91**:642–654, 1993
4. Constantian MB: An alternative strategy for reducing the large nasal base. *Plast Reconstr Surg* **83**:41–52, 1989
5. Constantian MB: Four common anatomic variants that predispose to unfavorable rhinoplasty results: a study based on 150 consecutive secondary rhinoplasties. *Plast Reconstr Surg* **105**:316–333, 2000
6. Daniel RK: The radix. In: *Aesthetic plastic surgery rhinoplasty*. Little Brown and Company, Boston, pp 151–168, 1996
7. Daniel RK: The radix and the nasofrontal angle. In: *Dallas Rhinoplasty Symposium*. pp 331–340, 1996
8. Daniel RK, Farkas LG: Rhinoplasty: image and reality. *Clinic Plast Surg* **15**:1–10, 1988
9. Farkas LG: Results. In: *Anthropometry of the head and face in medicine*. Elsevier, North Holland, New York, pp 28–30, 1981
10. Farkas LG, Hreckzko TA, Kolar JC, Munro IR, Chir B: Vertical and horizontal proportions of the face in young adult North American Caucasians: revision of neoclassical canons. **75**:328–336, 1984
11. Farkas LG, Kolar JC, Munro IR: Geography of the nose: a morphometric study. *Aesthetic Plast Surg* **10**:191–223, 1986
12. Farkas LG, Munro IR: *Anthropometric facial proportions in medicine*. Thomas, Springfield, IL, pp 167–169, 1987
13. Farkas LG, Shom P, Katic MJ, Munro RI, Chir B: Inclinations of the facial profile: art versus reality. *Plast Reconstr Surg* **75**:509–519, 1985
14. Goldman IB: Removal of the nasal hump. *Arch Otolaryngol* **74**:51–55, 1961
15. Gunter JP: Facial analysis for the rhinoplasty patient. In: *Dallas Rhinoplasty Symposium*. 1996: 23–24.
16. Guryon B: Precision rhinoplasty: Part I. The role of life-size photographs and soft tissue cephalometric analysis. *Plast Reconstr Surg* **81**:489–499, 1988

17. Guryon B: Precision rhinoplasty: Part II. Prediction. *Plast. Reconstr Surg* **81**:500–550, 1988
18. Lessard M-L, Daniel RK: Surgical anatomy of septorhinoplasty. *Arch Otolaryngol* **111**:25–29, 1985
19. Powell N, Humphreys B: *Proportions of the aesthetic face*. Thieme-Stratton, New York, pp 64–67, 1984
20. Sheen JH: Radix. In: *Aesthetic rhinoplasty*. Quality Medical Publishing St. Louis 70741984
21. Sheen JH: Th radix as a reference in rhinoplasty. *Perspect Plast Surg* **1**:33–35, 1987
22. Sheen JH, Sheen AP: *Aesthetic rhinoplasty*. St. Louis, Mosby, pp 1322–1327, 1142–1165, 808–826, 1987
23. Tardy ME, Brown R: *Rhinoplasty: the Art and the science*. WB Saunders, Philadelphia, PA, pp 453–459, 1997
24. Webster RC, Davidson TM, Smith RC: Nasofrontal angle changes in rhinoplasty. *Otolaryngol Head Neck Surg* **87**:95–108, 1979
25. Yellin SA: Aesthetics for the next millennium. *Facial Plast Surg* **13**:231–239, 1997